


# Percutaneous transgastrostomic interventional radiology-operated endoscopy facilitates foreign body removal using rigid endobronchial forceps

Mamdouh Khayat 

Jawad S. Hussain 

Jeffrey Forris Beecham Chick 

Anthony N. Hage 

Ravi N. Srinivasa 

## ABSTRACT

Retained foreign bodies within the stomach and proximal small bowel may be problematic in patients with prior cerebrovascular injury or head, neck and esophageal malignancy, given the increased vulnerability of this patient population to complications from aspiration and increased difficulty of esophagogastroduodenoscopy in cases of tumoral obstruction. This article presents an alternative method for foreign body retrieval through an existing gastrostomy tract, which offers the benefits of fast procedure times, reduction in radiation dose and fluoroscopy time, and allows for safer retrieval of foreign bodies by using direct visualization. This technique may be performed entirely by interventional radiologists.

**T**hough the placement of gastrostomy and gastrojejunostomy tubes has evolved with utilization of endoscopic and fluoroscopic-guidance, the principal role in facilitating enteral nutrition in patients unable to maintain adequate oral caloric intake remains unchanged (1). Patients with cerebrovascular injury or degenerative central nervous system disorders are predisposed to complications from aspiration. Head and neck and esophageal malignancies, neuroinvasion, or direct physical obstruction by tumor may result in dysphagia. Enteric tube placement thus becomes invaluable in this patient population.

In cases of persistent aspiration post-enteric tube placement or gastrointestinal bleeding, endoscopic evaluation to exclude concomitant pathology may be more complicated. The incidence of cardiopulmonary complications related to conscious sedation during endoscopy is well-documented (2–4). Given the increased vulnerability of this patient population to complications from aspiration and increased difficulty of esophagogastroduodenoscopy in cases of tumoral obstruction, alternative methods to visualize the gastrointestinal tract should be considered. Endoscopy through existing gastrostomy tracts has been documented infrequently, though has proven to be safe in the evaluation of upper gastrointestinal pathology (5–8).

The purpose of this study is to report the feasibility of performing interventional radiology-operated transgastrostomic endoscopy and endobronchial forceps retrieval of retained foreign bodies in patients with existing gastrostomy or gastrojejunal tubes. Such a technique offers an opportunity for interventional radiologists to broaden their role in comprehensive patient care.

## Technique

### Transgastrostomic interventional radiology-operated endoscopy

A schematic diagram of interventional radiology-operated transgastrostomic endoscopy for the removal of foreign bodies is shown in Fig. 1. All patients were evaluated by an attending interventional radiologist in clinic or in the emergency department. All transgastrostomic endoscopy procedures were performed entirely by interventional radiologists with 1–5 years of experience. All procedures were performed using intravenous moderate sedation with midazolam (Roche) and fentanyl (Akorn Pharmaceuticals) or general anesthesia administered by a certified registered nurse anesthetist or attending anesthesiologist. The

From the Division of Vascular and Interventional Radiology (M.K., J.S.H., J.F.B.C., R.N.S. ✉ [rnsriniv@med.umich.edu](mailto:rnsriniv@med.umich.edu)), Department of Radiology, University of Michigan Health Systems, Ann Arbor, MI, USA; and University of Michigan Medical School (A.N.H.), Ann Arbor, MI, USA.

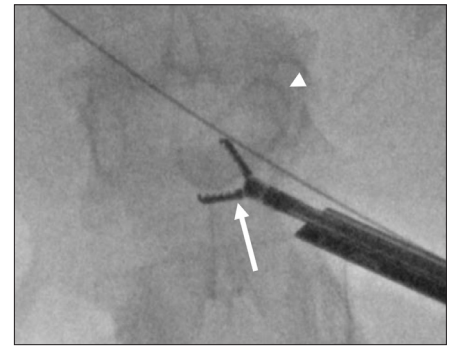
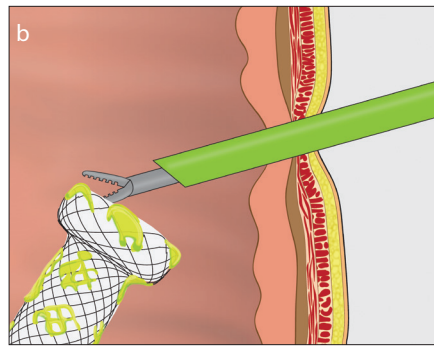
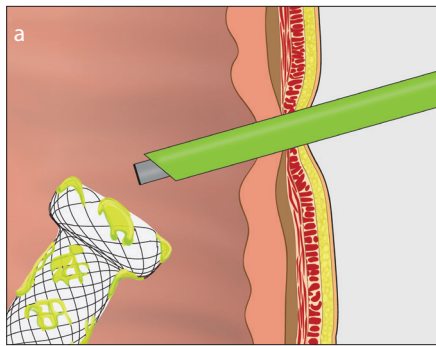
ORCID iDs of the authors: M.K. 0000-0002-3601-8507; J.S.H. 0000-0002-7748-4539; J.F.B.C. 0000-0001-9626-6142; A.N.H. 0000-0002-3502-1616; R.N.S. 0000-0003-0984-3664.

Received 26 October 2017; accepted 31 October 2017.

Published online 8 December 2017.

DOI 10.5152/dir.2017.17431

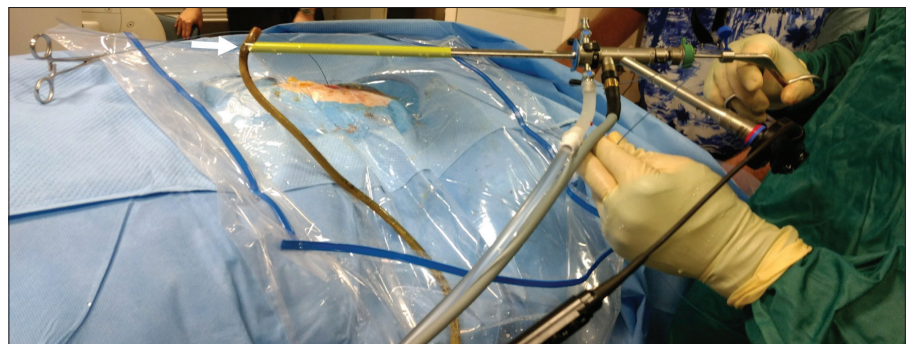
You may cite this article as: Khayat M, Hussain JS, Chick JFB, Hage A, Srinivasa RN. Percutaneous transgastrostomic interventional radiology-operated endoscopy facilitates foreign body removal using rigid endobronchial forceps. *Diagn Interv Radiol* 2018; 24: 42–45.



**Figure 1. a, b.** Schematic illustration of transgastrostomic interventional radiology-operated endoscopy. In panel (a), following dilatation of the gastrostomy tract, a 24 F Bard X-Force plastic sheath is advanced through the tract and a 22.5 F Olympus rigid endoscope is introduced into the gastric lumen through the sheath. Panel (b) shows 3 mm rigid endobronchial forceps introduced through the 4 mm working channel of the endoscope to retrieve the retained foreign body.

**Figure 2.** A 21-year-old male with cystic fibrosis and fractured Ponsky gastrostomy. Image demonstrates successful capture of the mushroom (*arrowhead*) with endobronchial forceps (*arrow*) through a rigid endoscope under direct endoscopic and fluoroscopic visualization.

epigastric region was prepped and draped in sterile fashion. The gastrostomy or gastrojejunostomy retention balloons were deflated and the existing tubes were cannulated and retracted over a guidewire. After fluoroscopic confirmation of a retained foreign body in the gastric lumen or duodenum, an 8 mm Bard X-Force (Bard Medical) balloon was utilized to dilate the gastrostomy or gastrojejunal tract. A 24 F Bard X-Force plastic sheath was then advanced through the dilated tract, and a 22.5 F Olympus rigid endoscope (Olympus Corporation of America) was introduced into the gastric lumen or duodenum. Then, 3 mm endobronchial forceps (Lymol Medical) were advanced through the 4 mm working channel of the endoscope and used to retrieve the retained foreign body under direct visualization. Fluoroscopy was used to confirm retrieval. After retrieval, and over the existing guidewire, a new gastrostomy or gastrojejunostomy was introduced under fluoroscopy. The tubes were secured by inflation of the reten-



**Figure 3.** A 47-year-old female with cerebral palsy and fractured jejunal limb of gastrojejunostomy. Image shows successful capture and removal of the jejunal limb (*arrow*) using the endobronchial forceps through a rigid endoscope.

tion balloons. The tubes were flushed and capped and the patients discharged.

Patients who underwent transgastrostomic foreign body removal are summarized in the Table.

#### Patient 1

A 21-year-old male with cystic fibrosis, pancreatic insufficiency, gastroesophageal reflux, cirrhosis, and malnutrition was referred to interventional radiology for routine exchange of his existing 24 F Ponsky, mushroom-retained, gastrostomy (Bard Medical).

The patient was brought to angiography suite for his scheduled exchange. Initial contrast (Isovue-M300; Bracco Diagnostics) injection through the existing gastrostomy confirmed patency and proper position. As the tube was retracted over the wire, the tube fractured with the fractured mushroom retained in the gastric lumen. The 22.5 F rigid endoscope was subsequently introduced into the existing gastrostomy tract and the fractured bumper was retrieved with 3 mm endobronchial forceps under direct visualization (Fig. 2). A new 22 F MIC-KEY gastrostomy

(Halyard Health) was placed. Follow-up at 140 days demonstrated no evidence of postprocedural complication or tube malfunction.

#### Patient 2

A 47-year-old female with cerebral palsy, spastic quadriplegia, and epilepsy was referred to interventional radiology for routine exchange of her existing 16 F gastrojejunostomy.

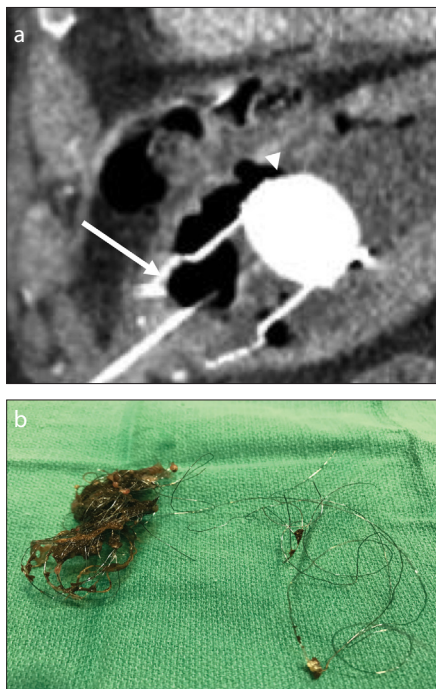
The patient was brought to the angiography suite for her scheduled exchange. Contrast injection (Bracco Diagnostics) through the existing gastrojejunostomy confirmed proper position. Upon retraction over a wire, the gastric component distal to the deflated balloon was noted to be fractured with retention of the more distal jejunal component within the duodenum. The distal fractured component could not be retrieved with hemostats. The 22.5 F rigid endoscope was subsequently introduced into the existing gastrojejunostomy tract and the fractured jejunal component was retrieved with 3 mm endobronchial forceps under direct visualization (Fig. 3). A

#### Main points

- Percutaneous transgastric endoscopy may facilitate the removal of foreign bodies from the stomach with minimal effort and low risk.
- Direct percutaneous endoscopic visualization for foreign body removal results in shorter fluoroscopy and procedure times.
- Percutaneous endoscopy may be performed by interventional radiology through existing gastrostomy tracts without the need for additional procedures with gastroenterology.
- Direct endoscopic visualization theoretically minimizes damage to normal tissue during endobronchial forceps retrieval of foreign bodies.

**Table.** Transgastrostomic foreign body removals

Patient	Age (years)	Foreign body	Location	Fluoroscopy time (min)	Procedure time (min)	Follow-up (days)	Technical success	Complications
1	21	Ponksy bumper	Stomach	12.8	54.2	140	100%	None
2	47	Jejunal limb	Duodenum	7.4	27.0	48	100%	None
3	65	Pyloric stent	Stomach	5.2	40.6	49	100%	None



**Figure 4. a, b.** A 65-year-old male with squamous cell carcinoma of the tongue and history of gastric outlet obstruction status post pyloric stenting complicated by stent migration and erosion into the gastric wall. Sagittal computed tomography image (a) demonstrates the gastrostomy balloon (arrowhead) serendipitously coursing through the stent which is retracted and partially eroding through the gastric wall (arrow). Image (b) following removal of the stent shows significant debris within the stent interstices.

new 18 F MIC-KEY gastrostomy was placed. Follow-up at 48 days demonstrated no evidence of postprocedural complication or tube malfunction.

### Patient 3

A 65-year-old male with squamous cell carcinoma of the base of tongue status post total laryngectomy, subtotal glossectomy, and bilateral neck dissection underwent surgical jejunostomy placement for enteral nutrition and separate percutaneous gastrostomy placement for decompression of gastric outlet obstruction. The patient

subsequently had an endoscopically-inserted Niti-S TTS esophageal stent (Taewoong Medical) placed across the pylorus for treatment of gastric outlet obstruction. The patient was referred to interventional radiology for exchange of both jejunostomy and gastrostomy tubes and, during preprocedural evaluation, was noted that the pyloric stent had migrated proximally into the gastric body and had been inadvertently cannulated by the gastrostomy tube during a prior tube exchange (Fig. 4a). A decision was made to retrieve the malpositioned pyloric stent. The patient was brought to the angiography suite for his stent removal. Contrast injection (Bracco Diagnostics) through the existing 18 F gastrostomy confirmed proper position. The gastrostomy was removed over a wire. The 22.5 F rigid endoscope was subsequently introduced into the existing tract and the malpositioned pyloric stent was retrieved with 3 mm endobronchial forceps under direct visualization (Fig. 4b). A new 22 F MIC-KEY gastrostomy was placed. Follow-up at 49 days demonstrated no evidence of postprocedural complication or tube malfunction.

## Discussion

This report describes a series of cases where endobronchial forceps retrieval was combined with interventional radiology-operated transgastrostomic endoscopy for retrieval of foreign bodies within the gastrointestinal system. While retrieval of endovascular devices such as inferior vena cava filters, guidewires, and stents has been reported, there is a paucity of published reports on enteric foreign body retrieval with combined endoscopy and endobronchial forceps.

All endoscopy procedures were performed entirely by interventional radiologists in this series. The present series utilized an 8 mm balloon to pre-dilate the gastrostomy tract in order to accommodate a plastic sheath and 22.5 F rigid endoscope. This afforded significant mobility as the plastic sheath could be rotated and torqued within the bowel lumen, allowing

for optimal positioning of the endoscope and forceps to retrieve foreign bodies. The use of endoscopy as an adjunct in the fluoroscopy-driven interventional radiology world may be beneficial. First, direct visualization of the target in three-dimensions allows for precise, purposeful movements without the need for continuous fluoroscopy. This limits radiation doses to the patient and the operator. In the event that the operator is unsure of their location within a structure, brief fluoroscopy may be used to reorient their position, moving back to the endoscopy monitor as the primary display. Average procedure time in these three cases was 40.6 minutes, while average fluoroscopy time was 8.4 minutes, suggesting that the majority of the procedure was completed endoscopically. While no direct comparative data is available for fluoroscopic enteric foreign body retrieval, conventional wisdom would suggest that fluoroscopy time would likely have been higher without endoscopic assistance. Secondly, when using devices such as endobronchial forceps within a hollow organ, the use of fluoroscopy alone limits the ability for the operator to assess their proximity to the mucosal surface of the bowel, making it easier for the operator to cause luminal injury while engaging the grasping mechanism. Directly visualizing the foreign body during capture may limit the inadvertent injury of bowel mucosa, improving overall safety.

With regards to sedation, one patient had a postsurgical airway, which necessitated the use of anesthesia services for routine tube exchange. A second patient expressed some discomfort while removing the existing tube while undergoing moderate sedation and thus deeper sedation was provided by an anesthesiologist. The third patient tolerated balloon dilation of the tract as well as transgastrostomic endoscopy with only local anesthesia. Patients vary in their degree of pain tolerance and need for procedural sedation and thus careful evaluation of a patient's pain tolerance and need for appropriate level of sedation is neces-

sary before pursuing transgastrostomic endoscopy.

In conclusion, transgastrostomic endoscopy and endobronchial forceps retrieval facilitates removal of gastrointestinal foreign bodies without complications. This may be performed entirely by interventional radiologists. Additional studies are warranted.

#### Conflict of interest disclosure

The authors declared no conflicts of interest.

#### References

1. Lyon SM, Pascoe DM. Percutaneous gastrostomy and gastrojejunostomy. *Semin Intervent Radiol* 2004; 21:181–189. [\[CrossRef\]](#)
2. Sharma VK, Nguyen CC, Crowell MD, et al. A national study of cardiopulmonary unplanned events after GI endoscopy. *Gastrointest Endosc* 2007; 66:27–34. [\[CrossRef\]](#)
3. Silvis SE, Nebel O, Rogers G, et al. Endoscopic complications: results of the 1974 American Society for Gastrointestinal Endoscopy survey. *JAMA* 1976; 235:928–930. [\[CrossRef\]](#)
4. Zubarik R, Fleischer DE, Mastropietro C, et al. Prospective analysis of complications 30 days after outpatient endoscopy. *Gastrointest Endosc* 2000; 52:703–704.
5. Adler DG, Gostout CJ, Baron TH. Percutaneous transgastric placement of jejunal feeding tubes with an ultrathin endoscope. *Gastrointest Endosc* 2002; 55: 106–110. [\[CrossRef\]](#)
6. Nishiwaki S, Araki H, Niwa Y, et al. Usefulness of transgastrostomic endoscopy (TGE) in patients with percutaneous endoscopic gastrostomy (PEG). *Gastroentereol Endosc* 2005; 47:49–55.
7. Nishiwaki S, Araki H, Shirakami Y, et al. Transgastrostomic endoscopy-assisted endoscopic submucosal dissection. *Endoscopy* 2009; 41: E13. [\[CrossRef\]](#)
8. Mori A, Ohashi N, Maruyama T, et al. Endoscopic retrograde cholangiopancreatography through a gastric stoma using an ultrathin endoscope: a novel approach. *Endoscopy* 2007; 39: E323. [\[CrossRef\]](#)